

The Periodontics Ltd.

Richard H. Yamada, D.D.S.
Douglas V. Gorin, D.D.S.
Richard F. Marinello, D.D.S.
Mark A. Rosen, D.D.S.
Stephen P. Russo, D.M.D., M.S.
Nadine Brodala, D.D.S., M.S., Dr. med dent

PerioDontaLetter



Periodontics Ltd., Periodontics, Orthodontics and Implant Dentistry

Spring

From Our Office to Yours...

One of the most difficult decisions a clinician has to make is when to save a tooth and when to remove and replace it.

This is a difficult decision on many levels.

Numerous factors must be considered including the restorability of the tooth, the patient's susceptibility to disease, gingival and papillary conditions, and esthetics in weighing the benefits vs. risks of retaining a compromised tooth.

The decision may be based on one critical issue or on a collection of factors.

*In this current issue of **The PerioDontaLetter**, we discuss these factors which need to be considered in deciding whether to remove or save a tooth.*

As always, we welcome your comments and suggestions.

To Save a Tooth or Replace It: That is the Question

Our goal as clinicians is to maintain or reinstate good form and function to the dentition with excellent esthetics and health.

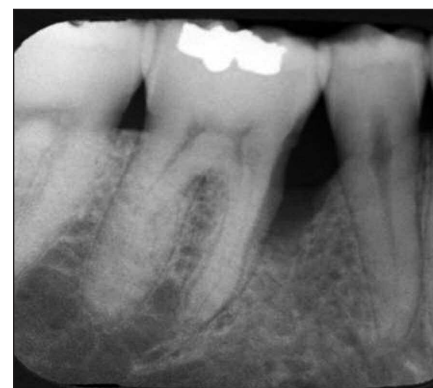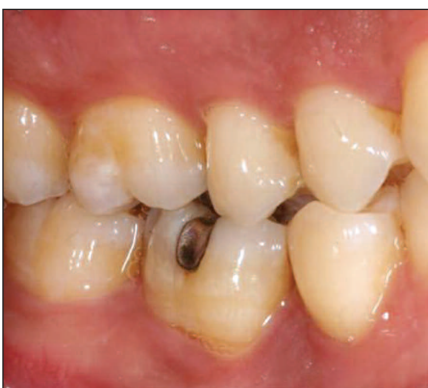Fundamental to developing a dental treatment plan, a prognosis must be assigned to each tooth.

Can it be saved?

Or, should it be removed and replaced with an implant?

Osseointegration and periodontal regeneration are two significant advances in contemporary dental care and each should be utilized when appropriate.

The natural dentition responds very well to definitive periodon-



Figures 1 & 2. The lower right first molar shows discoloration of the gingiva on the mesial aspect. Radiographically, an extremely large infrabony defect is revealed on the mesial aspect. Treat or Extract?

tal treatment. And there is significant evidence that efficacious periodontal treatment can change the prognosis of a tooth from hopeless to good.

Extracting teeth which have lost supporting periodontium and replacing them with dental implants is not always the preferred treatment approach.

Implant replacement is not infallible and does not mean the patient will not experience future complications.

While osseointegration has reduced the need to save teeth with a marginal prognosis, there has been a significant rise in the incidence of peri-implant disease and bone loss associated with dental implants.

Greenstein et al raise several questions when deciding whether a tooth should be saved or replaced.

These include:

1. Can the tooth be restored effectively?
2. Will endodontic treatment be successful?
3. Is periodontal therapy a reasonable option?
4. What effect will extraction have on the final treatment plan, particularly with respect to esthetics?

Restorative Considerations

An effective restoration can return teeth to normal function and acceptable esthetics.

Teeth without extensive caries, a favorable crown/root ratio and adequate tooth structure offer the best prognosis for effective restoration.

Fractures and Faulty Restorations. If a tooth is fractured, the clinician should make his or her best judgment to determine restorability.

Restorations must not infringe on the biologic width which can result in chronic gingival inflammation, pain and clinical attachment loss.

Problematic teeth in the esthetic zone which require a crown lengthening procedure should be evaluated for replacement because these measures may result in an unesthetic appearance due to excessive tooth length.

Essential to cosmetic success is a complete evaluation of the smile line and other factors.

Caries. Decay which extends beyond or to the level of the alveolar bone usually represents a restorative challenge for the clinician and substantial treatment costs for the patient.

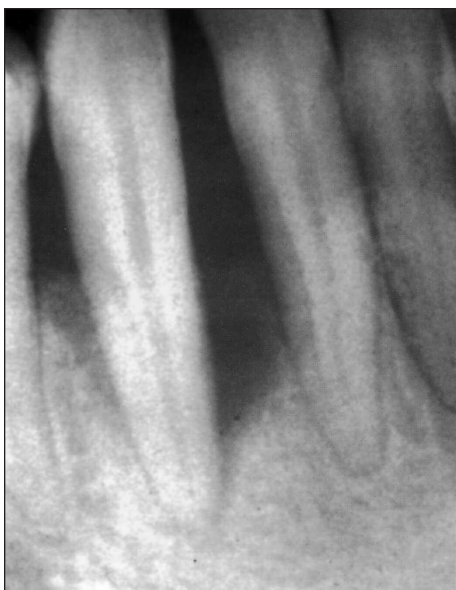

Figure 3. Most clinicians would be quick to remove the lower left canine which has severe bone destruction.

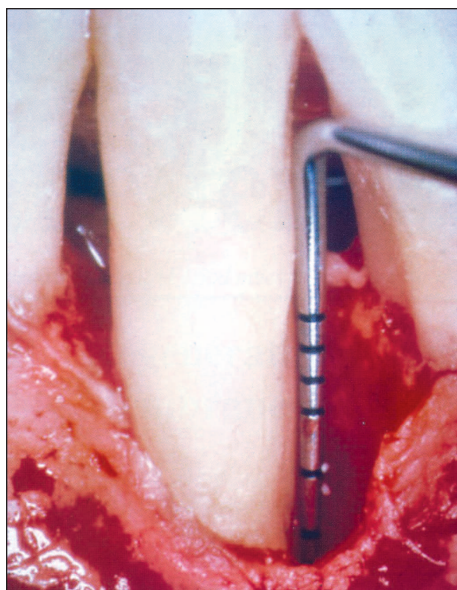


Figure 4. Following debridement of the osseous defect, the severity of bone loss can be observed.

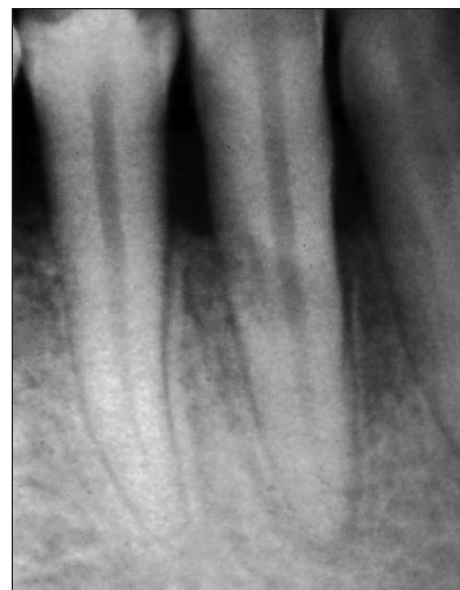

Figure 5. Six months following regenerative therapy, complete fill of the periodontal defect can be observed radiographically.

If a tooth is restorable, orthodontic extrusion, crown lengthening, or mucogingival surgical procedures may be required to salvage the tooth.

Crown/Root Ratio. Teeth without loss of attachment or destruction of periodontal tissues usually present a favorable crown/root ratio and consequently are good candidates for restoration.

A 1:1 crown to root ratio is the minimum acceptable assuming the periodontium is healthy and the occlusion is controlled.

Remaining Tooth Structure. Teeth with 5mm suprabony structure, 2mm for the biologic width, 2mm for the ferrule and 1mm sulcus depth are candidates for effective restoration.

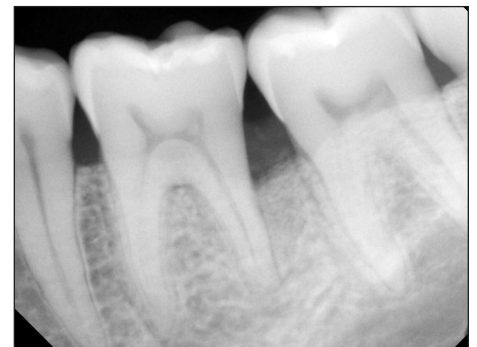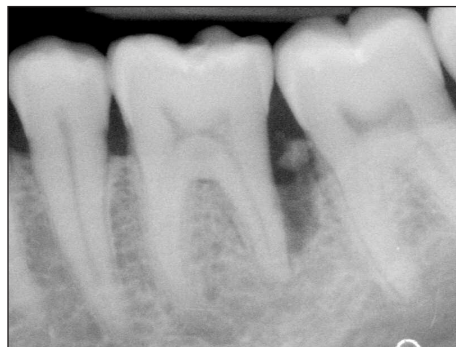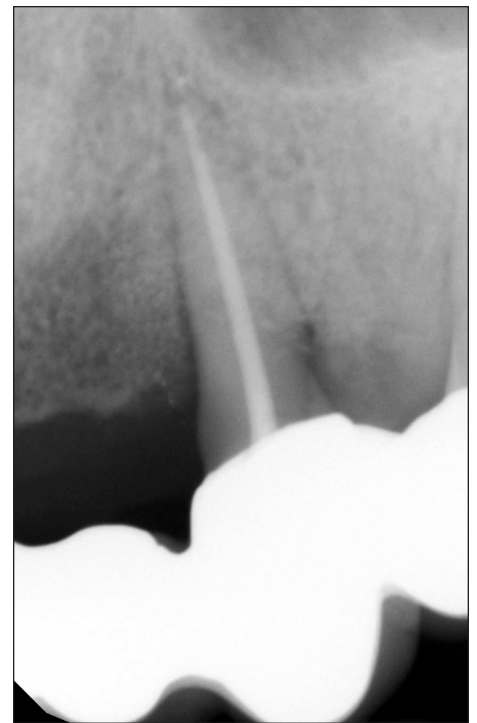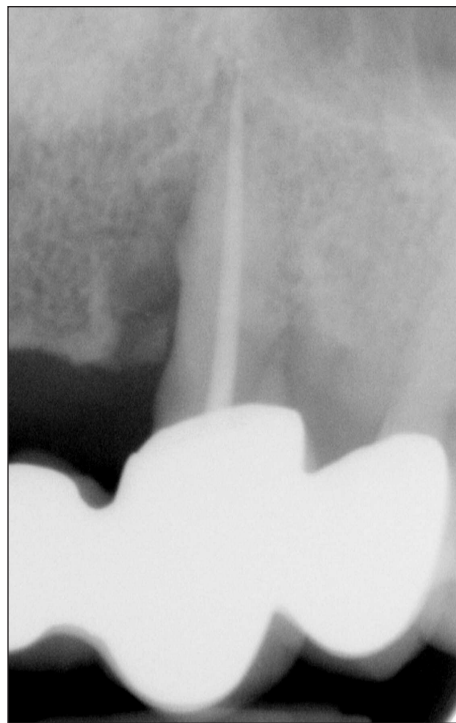Often the length of the available tooth structure is insufficient to ensure the preservation of the biologic width and crown lengthening may be required.

This makes the final cost similar, if not greater, to that of a single implant.

The final decision is often linked to financial considerations and the concern for longevity of the result as opposed to the possibility of saving an already compromised tooth.

Endodontic Treatment

Survival rates for endodontically treated teeth have been estimated to be as high as 95 percent when associated with an excellent full coverage restoration -- if the tooth is treated with a well-fitting single-tooth crown with adequate ferrule.



Figures 6, 7, 8 & 9. In the era of implant dentistry, too frequently teeth that can be saved are removed. These two cases illustrate how successful regeneration procedures can save teeth and return them to periodontal health.

Avila et al suggest the clinician should consider removing the tooth and replacing it with a dental implant if:

- The tooth has a large apical lesion (greater than 5mm).
- The tooth has had apical surgery.
- The tooth needs a large post and core for support.
- The tooth has inadequate ferrule.

- The tooth has an abnormal root anatomy precluding successful endodontic obturation.
- The tooth has a root which is short or thin which will cause a post to predispose the tooth to post loosening or root fracture.
- There is a misaligned post that will weaken the root structure.

“Tooth extraction and implant placement may not be the best therapeutic approach in all patients. The decision to save a tooth or extract it and place an implant must include a consideration of a multitude of factors.”

Periodontal Therapy

In deciding whether to save or replace a periodontally involved tooth, the clinician needs to consider the severity of the periodontal condition and the likelihood of recurrence.

If the periodontal prognosis is poor and/or the possibility of recurrence of the disease is high, such teeth may be candidates for removal and replacement with dental implants.

We suggest regeneration will most likely be successful in teeth with pocket depths greater than 6mm.

In addition, Avila et al suggest regeneration will most likely be successful in the following cases:

- Teeth with mobility greater than normal and up to 1mm in any direction. In addition to periodontal regeneration, these teeth can also be considered for splinting in case of secondary occlusal trauma.
- Teeth with no recurrent periodontal abscess.
- Teeth with less than 30 percent alveolar bone loss
- Teeth with deep, localized narrow intrabony defects.
- Teeth without invasive furcation involvement
- Teeth without interproximal bone levels equal to or apical to the level of the furcation.

- Teeth with no root anomalies.
- Teeth which would benefit from root resection as a conservative, therapeutic option.

Avila et al suggest teeth should be considered for replacement if:

- Pockets are deeper than 8mm.
- Teeth are extensively mobile.
- Teeth have recurrent periodontal abscesses.
- Teeth have root anomalies -- cervical enamel projections, enamel pearls or root grooves.

Esthetic Considerations

If function and cosmetics can not be maintained or improved, this may be an indication for tooth removal.

The decision to retain a tooth or remove and replace it with an implant is dependent on the ability to achieve a functional and cosmetic result.

The Effect of Retention or Replacement on the Final Treatment Plan

The strategic value of a particular tooth is an important parameter to be considered when designing a

treatment plan. The decision to extract or retain teeth affects adjacent teeth, especially if the plan is for the teeth to function as abutments for a fixed or removable partial denture.

It is essential to determine if a compromised tooth can withstand the functional load anticipated in the future.

Other Considerations

Other factors in the decision to retain or remove teeth are:

- Smoking habits
- Use of IV bisphosphonates and other drugs
- Patients with uncontrolled systemic conditions such as Type 1 diabetes

Conclusion

Tooth extraction and implant placement may not be the best therapeutic approach in all patients.

The decision to save a tooth or extract it and place an implant must include a consideration of a multitude of factors.

