


PerioDontaLetter



Periodontics LLC, Periodontics, Orthodontics and Implant Dentistry

Summer

From Our Office to Yours...

Peri-implant diseases are a growing problem in implant dentistry. Infectious in nature, they can be classified into two types: peri-implant mucositis and peri-implantitis. Peri-implant mucositis is an inflammatory lesion residing only in the mucosa. Peri-implantitis affects both the peri-implant soft tissues and the supporting bone.

Although restorations of endosseous implants have demonstrated a very high success rate, one study found 80 percent of patients had peri-implant mucositis in half their implants; and 56 percent of patients also had peri-implantitis in 43 percent of their implants.

*This current summer issue of **The PerioDontaLetter** addresses the causes, prevention and treatment of peri-implant disease. As periodontists, our focus is the treatment and stabilization of these conditions.*

As always, we welcome your questions and comments in our collaboration to manage these common conditions.

Peri-Implant Disease: Causes, Prevention and Treatment

As with all periodontal diseases, early diagnosis of inflammation of the peri-implant tissues adjacent to implants is key to successful treatment.

Radiographs should be taken at the time of implant insertion to determine baseline alveolar bone levels. Radiographs should also be taken at the time of prosthesis delivery and one year later. These can then be compared to future radiographs to determine if crestal or peri-implant bone loss has occurred.

Peri-implant diseases often do not become clinically evident for a num-

ber of years after restoration. Careful clinical monitoring of implants can find early changes in clinical parameters. Clinical features of peri-implant mucositis include, but are not limited to, bleeding on probing, swelling of the peri-implant mucosa, increased probing depths (mainly pseudo-pockets), and/or erythema of the surrounding tissues.

Peri-implantitis can be characterized by bleeding or suppuration upon probing, increased pocket depth and swelling or fistula formation; and additionally pain on chewing and radiographic bone loss.

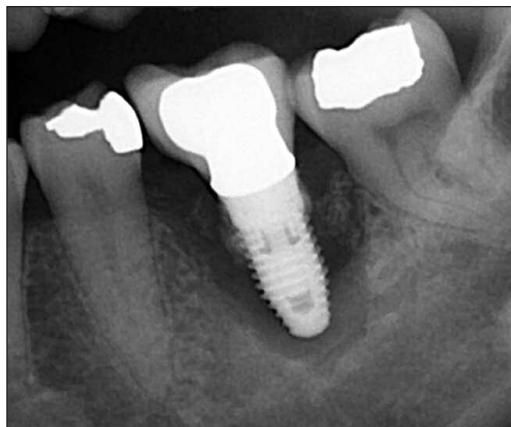

Figure 1. If not caught in its early stages, peri-implant disease can progress and destroy the entire bone support for an implant.

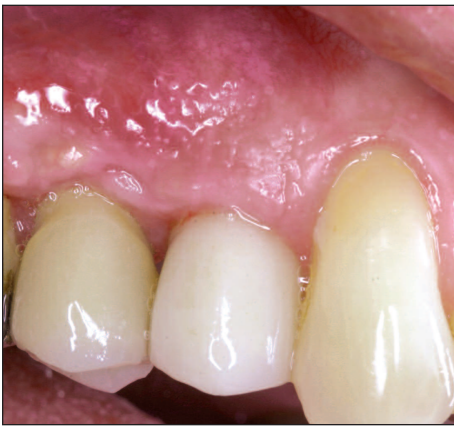

Figure 2. One year after implant placement, a fistula is forming on the buccal of the upper second premolar.

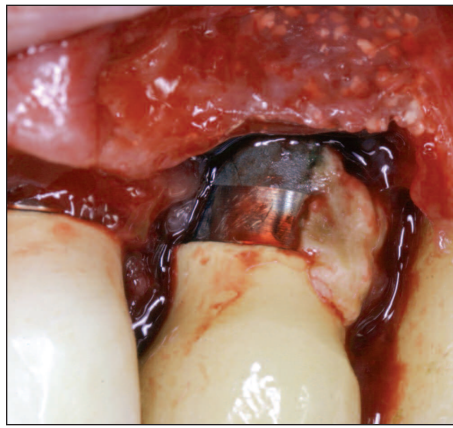


Figure 3. On flap reflection, excess cement appears to be the etiology of the bone destruction.

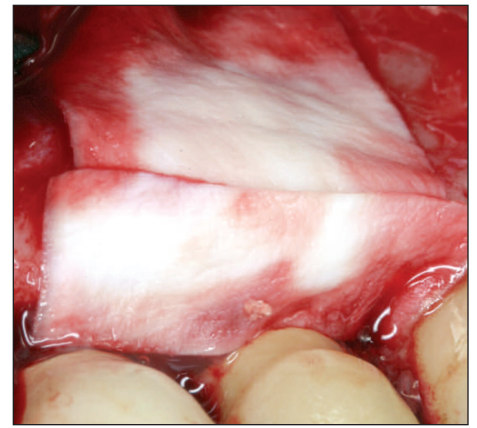


Figure 4. The cement was removed and a bone graft and a barrier membrane were placed to attempt to regenerate the lost bone support.

Causes of Peri-Implant Disease

Local iatrogenic factors can play a significant role in the development of peri-implant disease. These include:

- excess cement
- bacterial biofilm
- incompletely-seated abutments
- open crown margins
- occlusal overload
- over-contouring of restorations, and
- poorly positioned implants

Several studies have shown chronic periodontitis increases the risk of peri-implant disease along with parafunctional habits (bruxism and malocclusion), systemic diseases such as diabetes and osteoporosis, and smoking. One study found that the bacteria found at implant sites affected with peri-implantitis was almost identical to the bacteria found in periodontitis.

Other studies indicate the width of keratinized gingiva affects the health of the supporting tissues around dental implants. Bouri et al found implants with narrow zones of keratinized tissue (less than 2mm) had more plaque and inflammation, were more prone to bleeding on probing, and presented with more bone loss.

Warriner et al found implants without keratinized mucosa demonstrated significantly more recession and slightly more attachment loss than implants with an adequate zone of attached gingiva.

One study suggested that implant surface characteristics (smooth vs. textured) also influence the progression of peri-implant disease.

Lindhe J et al found that because there are biologic differences between teeth and implants, the progression of infection around implants is somewhat different than it is around natural teeth. The inflammatory cell infiltrate around implants was reported to be larger and extend more apically when compared to a corresponding lesion in the gingival tissue around natural teeth due to the lack of cementum.

In addition, the tissues around implants are more susceptible to plaque-associated infections that spread into the alveolar bone primarily due to the lack of a periodontal ligament.

The routine soft tissue healing response to a majority of implant and abutment surfaces is a parallel arrangement of connective tissue fibers. This arrangement is described as a seal rather

than an attachment compared to the connective tissue attachment seen with natural teeth.

Recent technological developments in dental implant collar design and abutments have demonstrated the ability to maintain stable crestal bone and biological width.

Preventing Peri-Implant Disease

Preventing the development of a biofilm and eliminating it from the implant surface should be the first steps in the preservation of peri-implant soft tissue health. This requires thorough oral hygiene instruction and strict patient compliance.

Adequate periodontal disease control is also essential in the partially-edentulous patient to prevent cross contamination from teeth to implants. Recent studies have found that the lack of preventive maintenance in individuals with pre-existing peri-implant mucositis was associated with a high incidence of peri-implantitis.

When restoring an implant, it is absolutely essential to ensure all excess cement has been removed and the area

is cleansable with an oral hygiene product such as an interproximal brush.

Cement peri-implantitis is one of the most significant reasons for marginal infection and bone loss. Studies by Wilson, Cobb and Callan have described pathological changes associated with excess cement. Shapoff and Lahey have discussed numerous factors leading to excess cement and discussed strategies to identify, diagnose and prevent excess cement around implants.

Adjusting the prosthesis to open the embrasure space will allow the patient easy access during home oral hygiene.

Pontic areas should be convex rather than concave in the area over gingival tissues to ensure plaque and food debris is easily cleansable.

Treating Peri-Implant Disease

Peri-implant mucositis is often a reversible condition and requires only minimal intervention to treat. Thorough mechanical debridement of the area along with local anti-microbials such as Chlorhexidine irrigation or Dentomycin or Arestin is usually sufficient to resolve the problem. A thorough examination of the area should also be completed to ensure there are no

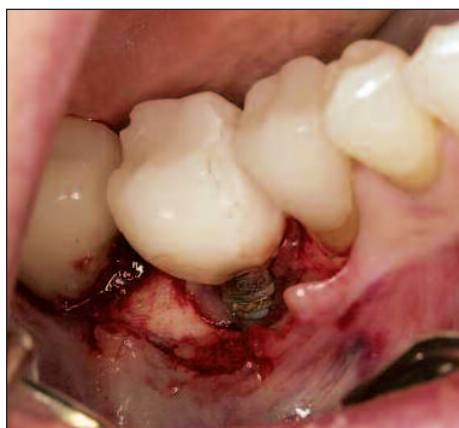

Figure 5. Coronal bone loss on this implant was the result of excess subgingival cement.

local iatrogenic factors contributing to the problem.

If the disease has progressed to peri-implantitis and bone loss is evident, initial treatment is the same: mechanical debridement, anti-microbials and strict oral hygiene protocols, including chlorhexidine mouthwash.

Administration of systemic or local antibiotics should also be considered to reduce the number of pathogens present. Adjunctive local or systemic antibiotics have been shown to reduce bleeding on probing and probing depths in combination with mechanical debridement. Culturing and / or DNA probes will identify the pathogenic bacteria and define which antibiotic will likely have the best result.

The basic goal in the treatment of peri-implantitis is decontamination of the infected abutment or implant surface. Unfortunately, to date, studies suggest that nonsurgical treatment of peri-implantitis is unpredictable and the use of chemical agents alone such as chlorhexidine has only limited effects on clinical and microbiological parameters.

Numerous methods are used to debride a plaque-contaminated abutment or implant surface including mechanical, sonic and ultrasonic scalers; lasers; air-powder abrasion and various chemical solutions such as citric acid, hydrogen peroxide and saline.

Beneficial effects of laser therapy on peri-implantitis have been shown, but this treatment needs to be further evaluated. Schwarz et al found the Er:YAG laser only improved peri-implant probing pocket depth and clinical attachment level for about six months.

Another study using access flap surgery with the application of a chemical agent (e.g., metronidazole gel) for decontamination showed favorable results.

In most situations, clinical parameters of soft tissue peri-implantitis can be improved with a variety of intervention-

al steps, however minimal bone remodeling is possible. Some success in well-contained four-wall defects has been achieved by removing the implant crown and abutment and attempting bone regenerative procedures after cover screw replacement, grafting and primary closure.

Bone Regeneration and Reosseointegration

Comparison of the various decontamination methods or their combined use did not show any significant differences in terms of bone regeneration and reosseointegration.

Once the implant surface has been decontaminated, the clinician can then consider whether to attempt to regenerate the bone around the implant based on the amount of bone loss, the defect morphology and the patient's motivation.

Access flap surgery in combination with decontamination of the implant surface seems to be the treatment modality that provides the best improvement of inflammation. Additional osseous recontouring of the bony architecture around the implant could be helpful in arresting further bone loss. Leonhardt et al found an

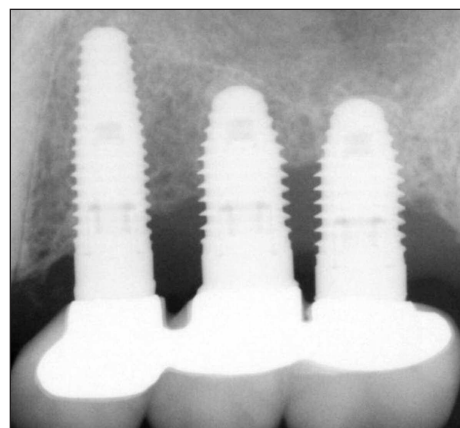


Figure 6. Peri-implant disease can cause bone destruction from one implant to another.

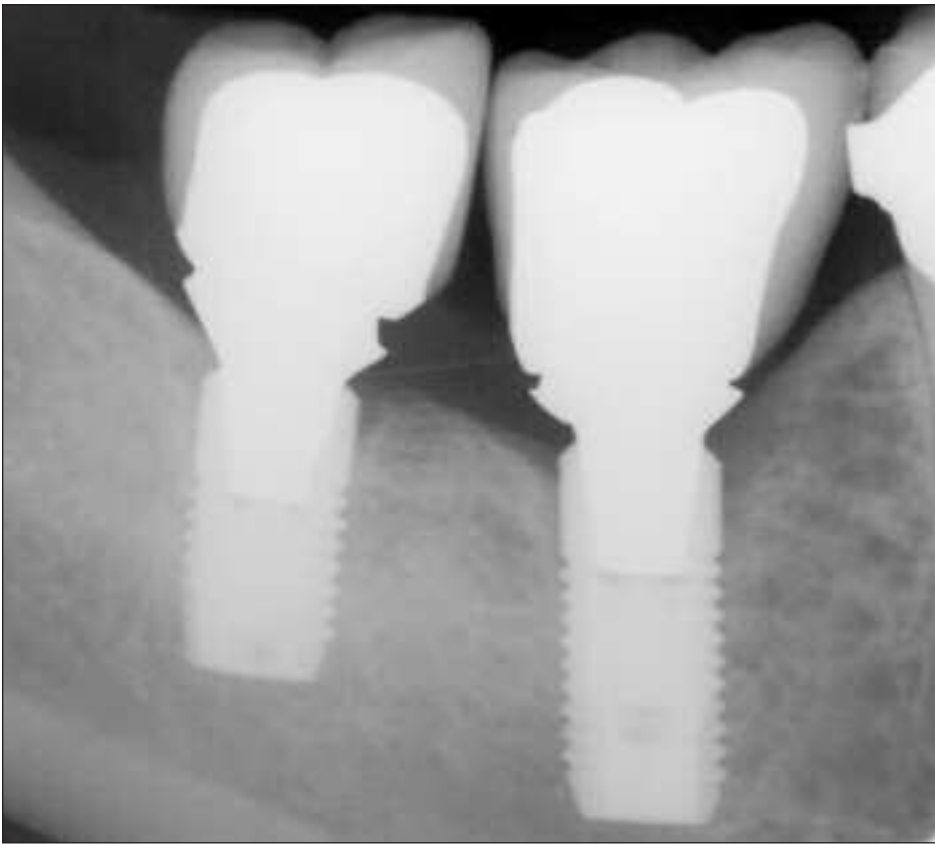


Figure 7. Improperly seated crowns can create a plaque trap leading to peri-implant disease and bone loss.

open flap surgical procedure combined with mechanical debridement of the implant surface was successful in decontaminating 58 percent of implants for five years.

If bone loss extends beyond half of the implant fixture length, it is often recommended the implant be removed, the site reconstructed, and then an implant replaced after successful bone augmentation. Guided bone regeneration using a bone graft and membrane has demonstrated the best success in achieving bone fill of the defects associated with peri-implantitis.

Studies show, however, that it is very difficult to regain osseointegration and obtain healthy peri-implant tissues once significant bone loss has occurred.

Modifying the surface of the contaminated implant surface topography can be used in combination with resective osseous surgery to correct the anatomical architecture of bone. Results showed that implant reshaping resulted in better improvement when compared with the control group (ie, flap debridement, systemic antibiotic, full mouth disinfection).

Augmentation of Keratinized Tissue

Some patients may need augmentation of keratinized tissue to maintain peri-implant health. But in the absence of data which reliably predicts who would benefit from tissue augmentation, ultimately this is a

judgment call which needs to be made by the clinician.

Greenstein and Cavallaro suggest there are situations where it seems logical that augmentation of keratinized gingiva would be beneficial:

1. Chronically inflamed sites where altering the gingival topography would make hygiene easier.
2. Locations with ongoing recession or continued loss of clinical attachment or bone, regardless of periodontal therapy and good oral hygiene.
3. Sites where the patient complains of soreness when brushing, despite the appearance of gingival health.
4. Dental history suggesting predisposition to periodontitis or recession.
5. Patients noncompliant with periodic professional maintenance.

Conclusion

Prior to implant placement, control of periodontal disease in other areas of the mouth is critical to preventing cross-infection of the implant.

It is also important to manage occlusal forces.

Retention of excess cement around the dental implant collar is a major reason for peri-implantitis that does not become clinically evident immediately after crown placement. In addition, recognition of excess cement is difficult and not always evident on radiographs.

Improved methods of cementation technique, shallow subgingival margins with the use of custom abutments and early and frequent follow-up visits in a shared maintenance approach will minimize the irreversible effects of cement peri-implantitis.

Treatment of peri-implantitis can improve soft tissue health; however, crestal bone loss around dental implants is difficult to correct.

The best method is prevention.

