

The Periodontics Ltd.

Richard H. Yamada, D.D.S.
Douglas V. Gorin, D.D.S.
Richard F. Marinello, D.D.S.
Mark A. Rosen, D.D.S.
Stephen P. Russo, D.M.D.

PerioDontaLetter



Periodontics Ltd., Periodontics, Orthodontics and Implant Dentistry

Spring

From Our Office to Yours...

Implant dentistry can effectively meet the restorative needs of fully and partially edentulous patients. However, both the implants and the restorations they support can fail in response to local and systemic etiologic factors.

The ability to assess the reaction of the peri-implant tissues and maintain their health is affected by improvements in the biology and mechanics that affect implant dentistry.

Implants are being fabricated from a variety of materials and their surfaces modified to enhance integration. The restorative components are being revised to facilitate clinical procedures and improve esthetics.

*In this current issue of **The PerioDontaLetter**, we focus on the assessment essential to precluding the onset of disease in the peri-implant tissues and protecting the restorative componentry.*

As always we welcome your comments and suggestions.

The Realities of Dental Implant Maintenance

Traditional implant maintenance has in the past included clinical assessment of plaque control and radiographic evaluation of the crestal bone levels.

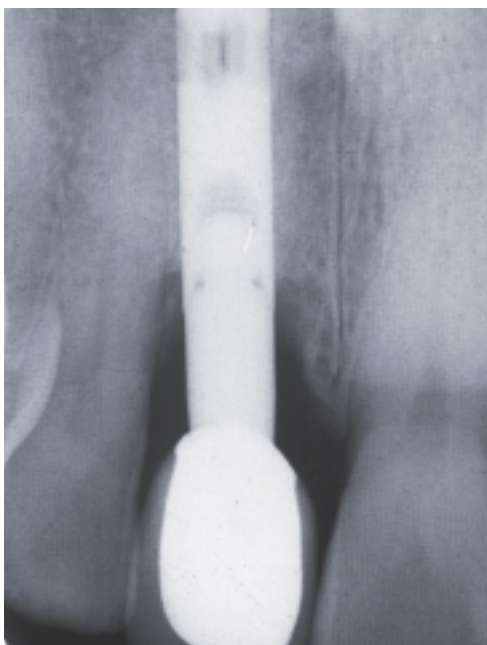
Additionally, it was important to determine the integrity of the connection of the prosthesis to the abutment and the abutment to the implant body.

The advent of single tooth and cemented restorations, early and immediate loading, the variety of abutment designs, and a shift in focus to more cosmetically-acceptable restorations has necessitated the development of changes in the concepts in implant maintenance.

To ensure the continued maintenance of optimum intraoral health,

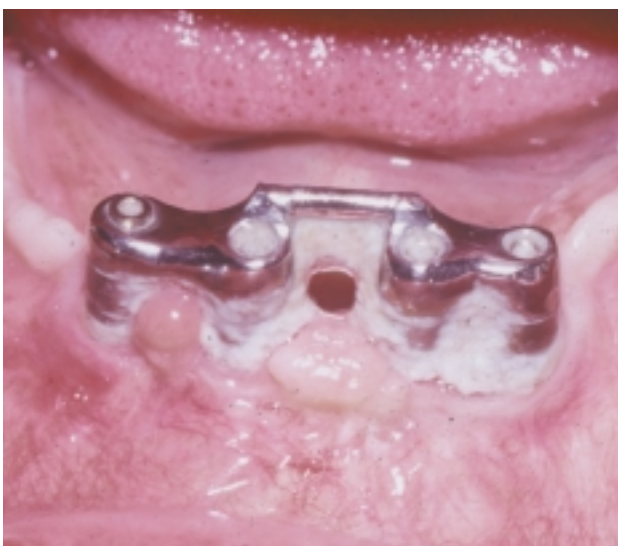
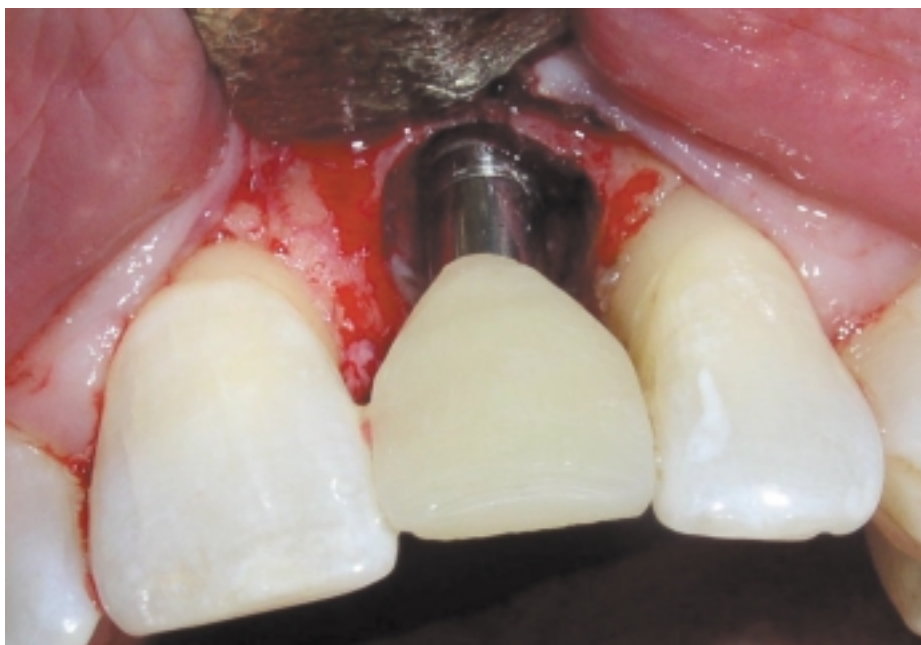
Figure 1.
**Who says
calculus can't
form on
implants?**



Figures 2 and 3. The extreme subgingival placement of this implant and the proximity of the microgap to the bone at the abutment implant interface contributed to this osseous defect.

the dental team must understand how to assess the health of the peri-implant tissues, the alveolar bone housing and the common restorative components associated with dental implants.

Following are some important issues to be considered at every dental implant maintenance appointment.

Peri-Implant Anatomy and Probing

Probing around implants is controversial. If probing is performed, the clinician should use light probing forces taking care not to detach the junctional epithelium or the connective tissue fibers.

Clinically and histologically, the soft tissue around teeth and implants resemble each other. Both are covered by epithelium and form a crevice which terminates apically at the junctional epithelium which is attached to the tooth and implant respectively. The epithelium is attached by a hemidesmosomal attachment similar to the junc-

tional epithelial attachment on the surface of a natural tooth.

However, the connective tissue between the junctional epithelium and the crest of the bone differs in several respects as a result of the absence of a periodontal ligament and cementum around an implant.

The peri-implant connective tissue contains more collagen and fewer fibroblasts and blood vessels as compared to the gingival tissue surrounding a tooth. The connective tissue around the implant is adherent and the collagen fibers run parallel to its surface. In contrast, the fibers within the connective tissue around teeth insert into the cementum of the root as Sharpey's fibers which creates a much stronger connective tissue attachment.

This structural dichotomy in the connective tissue relationships helps to explain the differences in response to the presence of inflammation. The inflammatory lesion around implants compared to that around teeth has been shown to be larger in size and to

progress more laterally, frequently extending directly into the bone marrow.

Evaluation of the peri-implant mucosa begins by determining whether the tissue is keratinized or non-keratinized. In some cases the lack of keratinized tissue around an implant can limit the patient's plaque control habits due to increased discomfort. Digital palpation of the tissue in the vicinity of the margin can reveal the presence of bleeding or suppuration.

The contours of the restoration and the emergence of the implant head at times may limit access or interfere with long axis placement of the probe. Thread design, the implant contours and the texture of the implant surface can restrict the path of the probe tip.

Implants are often placed deeper than would be the location of the CEJ of a tooth, especially in the esthetic zone, to permit development of an optimal emergence profile and contours of the restoration. If the proximal crestal bone levels of the adjacent teeth are more coronal than the implant platform, non-

pathologic interproximal “pockets” may be as deep as 6-7mm without necessitating corrective treatment. We recommend that supportive periodontal-implant maintenance visits be shared with the periodontist to ensure that necessary intervention is never delayed.

Bacteria

In treating partially-dentate patients it is especially important that they be in optimum periodontal health and periodontal disease is under control **before** dental implants are placed. We recommend a consultation between the primary care dentist and the periodontist, including analysis of pertinent diagnostic records, prior to the development of the treatment plan.

Crucial to the success of an implant restoration is the patient’s plaque control and debridement by the hygienist. Various studies clearly show that lack of effective plaque control results in peri-implantitis and adversely affects the success rate of the implant and implant-supported restorations.

A healthy implant crevice will have a microbial flora consisting predominantly of gram-positive cocci and non-motile rods. Diseased implant crevices exhibit populations of gram-negative anaerobic rods and spirochetes, similar to the periodontal pathogens found in pockets associated with periodontitis around natural teeth.

There are also significant microbial differences between the fully and partially dentate patient. The teeth may harbor putative periodontal pathogens and serve as a bacterial reservoir which ultimately contribute to colonization around the implants. A recent paper documents a more specific trend in which such organisms are transmitted from teeth to implants in the same arch.

Restoration Stability

The integrity and stability of the restoration must be checked periodically to determine cement wash out, screw loosening or fracture, damage to the

integrity of the prosthesis and, occasionally, fractures of the implant body.

Any lateral or apical-coronal mobility of an implant is generally synonymous with the loss of integration. Evaluating mobility is particularly important if one encounters any of the well-known clinical signs of peri-implant inflammation. Radiographic changes suggesting loss of alveolar height or bone alongside the surface of the implant body also demand further examination. Radiographs are also reliable indicators of alterations in the integrity of component connections.

Perhaps the most significant finding is ANY DISCOMFORT reported by the patient or elicited when “stressing” the implant, by pushing, torquing, or while in function.

Some of the most important aspects of the restoration to evaluate are:

- Status of surface material (fractures/chipping of porcelain/composite)
- Integrity of solder joints
- Loss of cement seal

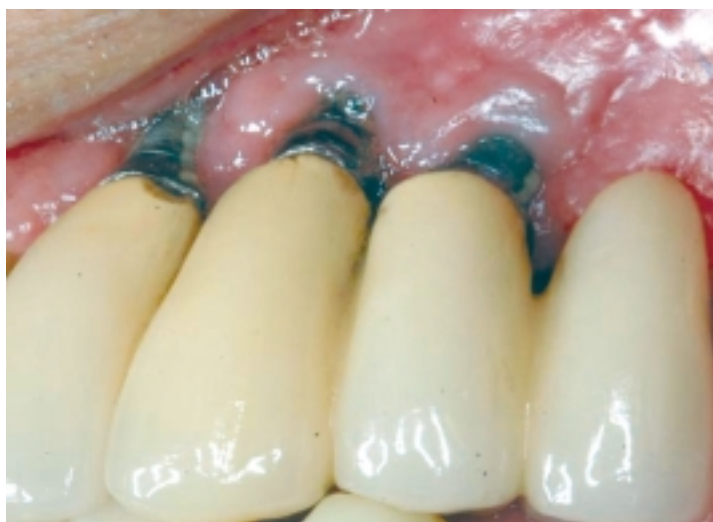

Figure 4. Peri-implantitis has caused significant inflammation of the gingival tissues with marked plaque deposition and recession characterized by underlying bone loss resulting in substantial exposure of the implant body.

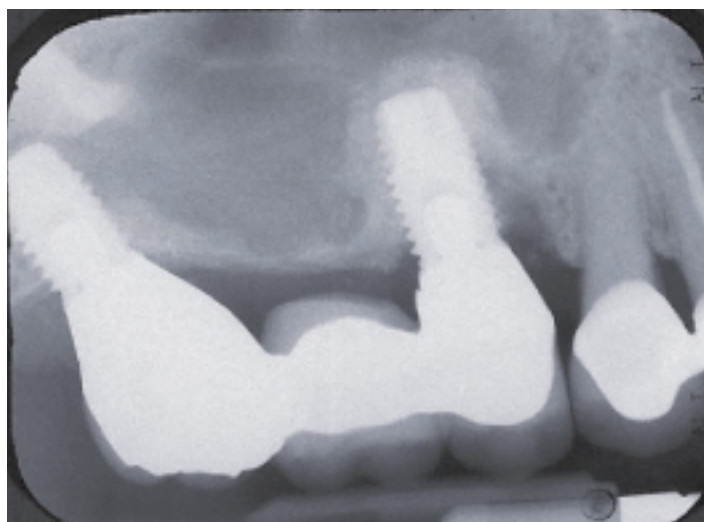


Figure 5. Mesial bone loss and subgingival infection will likely lead to the loss of this implant.

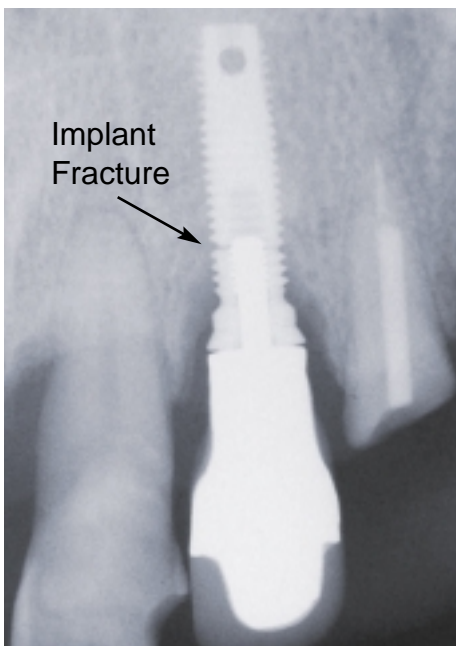


Figure 6. Radiographic evidence of a fractured implant. Bone loss can be seen to have progressed apically to the fracture.

- Loose screws or fractures
- A tight seal on screw access holes
- Occlusal relationships (guidance, interferences, etc.)
- Excessive wear patterns on the restoration or opposing occlusion

One of the most destructive and potentially devastating findings is that of subgingival cement. Due to the extremely close fit of a cast restoration to a milled implant abutment, special care and excellent technique is essential during and immediately after cementation. This can be most challenging in situations where implants are intentionally placed deep for cosmetic purposes.

Movement of an implant-supported restoration may signal:

- Inaccurate fit of the superstructure leading to potential damage or fracture of the restoration
- Loose screws subject to deformation and fracture

- Persistent irritation of the surrounding soft tissues, leading to failure of the junctional epithelial attachment
- Parafunctional habit patterns

The Possible Significance of the “Micro-Gap”

Many longitudinal studies have suggested that marginal recession and crestal bone loss may occur over time, even in a well-integrated implant. It has been suggested that this may be related to peri-implant inflammatory changes, which may be associated with the micro-gap and the formation of a biologic width among other possibilities.

The term micro-gap usually refers to the junction of the interface between the abutment and the implant platform or the marginal adaptation of the restoration to the abutment. The “gap” is often located subgingivally and it may provide a locus for plaque retention and colonization of pathogenic bacteria. We must be eternally vigilant because the presence of subgingival bacteria can be destructive to implants as it is to natural teeth.

Radiographs

We have found vertical bitewings and parallel periapical films are essential to evaluate crestal bone levels around implants. These may be as useful as probing to determine interproximal health or disease around implants.

Our suggested protocol is to obtain a baseline film at the time of insertion of the final prosthesis, retaken six months and one year thereafter, and then every two years hence. This frequency should be altered to fit the individual needs of each patient and especially in the face of

systemic and/or clinically observed changes.

Crestal bone changes within the first year the implant restoration is loaded should be no greater than 2.0mm, depending upon the implant system. Subsequent changes in crestal bone levels should be limited to 0.1mm/year. Since accurate and reproducible measurements of this magnitude (less than 1mm) are difficult to assess clinically, any observable radiographic changes should be treated promptly and aggressively, with an emphasis on the specific etiology of the attachment loss.

Systemic Influences

Certain systemic influences may interfere with osseointegration and adversely affect implant prognosis. As a patient’s systemic condition changes for the worse, negative influences on local etiology and the physiologic response of the surrounding soft tissues and bone are not unusual. Smoking and many medications also affect oral flora, soft tissue and bone metabolism.

Common systemic diseases such as diabetes and osteoporosis have been demonstrated to affect the bone-to-implant contact. It is well known that medications such as calcium channel blockers and immunosuppressants may have a profound effect on the inflammatory response of the peri-implant environment. Bisphosphonate drugs used to treat a variety of bone metabolism disorders can also lead to bisphosphonate-related osteonecrosis (BROCN) of the jaws, following tooth extraction.

As with any patient, a regular, updated medical history is of critical importance.

