

The Periodontics Ltd.

Richard H. Yamada, D.D.S.
Douglas V. Gorin, D.D.S.
Richard F. Marinello, D.D.S.
Mark A. Rosen, D.D.S.
Stephen P. Russo, D.M.D., M.S.
Nadine Brodala, D.D.S., M.S., Dr. med dent

PerioDontaLetter



Periodontics Ltd., Periodontics, Orthodontics and Implant Dentistry

Spring

From Our Office to Yours...

Along with the increase in the population over the age of 62 who are keeping their natural teeth longer has come an increase in the prevalence of root caries, root fractures and root sensitivity.

This newsletter reviews current trends in the prevention, diagnosis, treatment and management of these growing root problems.

As always, we welcome your questions and comments in our collaboration to manage these common conditions.

Your practice is very important to us. It is always our goal to partner closely with you to support your practice, strengthen our professional relationship and increase the effectiveness of our teamwork.

We hope this newsletter is a valuable source of information which you have been able to integrate into your practice.

We thank you for your referrals and as always, when you refer a patient to us, we do our utmost to live up to the confidence you have placed in us.

The Root of the Problem: Root Caries, Fractures and Sensitivity in the Adult Periodontal Patient

The incidence of root caries in the adult periodontal patient is increased by a number of factors, including gingival recession, diet, poor oral hygiene, periodontal disease, xerostomia produced by many common medications, Sjogren's disease, chemotherapy and radiation treatment.

Diagnosing, treating and avoiding root fractures present some of the most

challenging restorative problems to dentists.

Moderate tooth root sensitivity reportedly affects ten percent of the general dental population.

Consequently, developing effective treatment regimens for managing these vexing problems could benefit many of our patients.

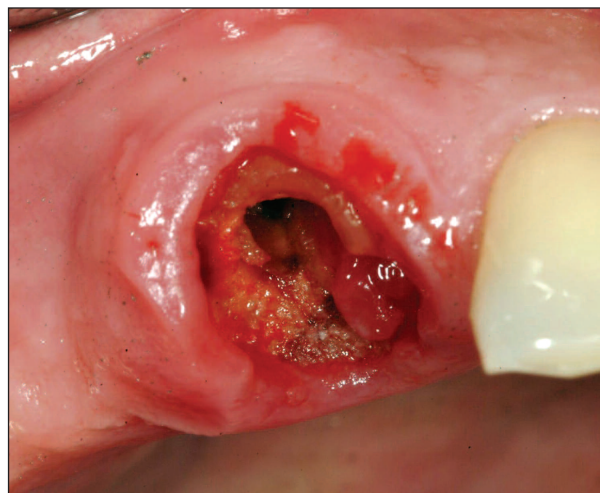


Figure 1. Root caries caused the loss of this post and crown and necessitated the removal of the tooth.

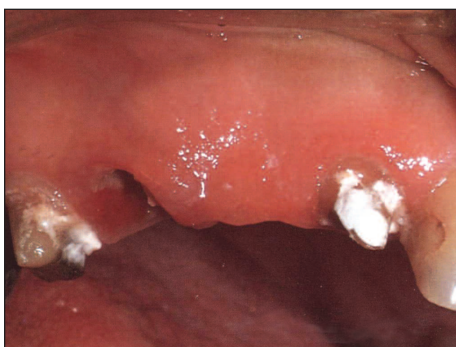

Figure 2. Subgingival root decay caused the loss of the existing prosthesis.

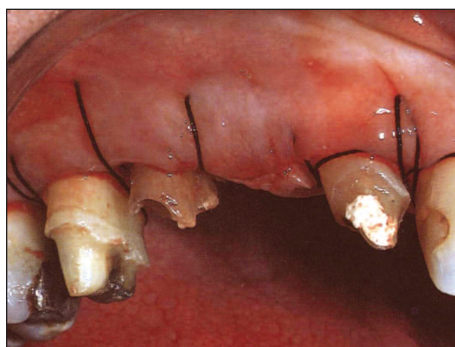


Figure 3. Crown lengthening was performed to assist in the construction of a new restoration.

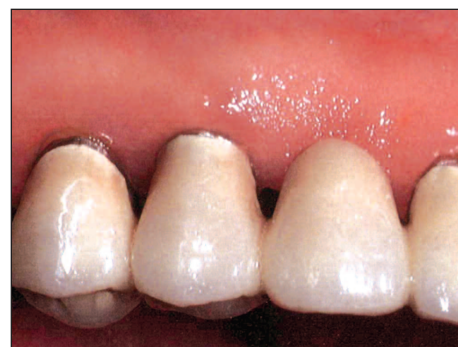

Figure 4. The final restoration three months post-op.

Root Caries

Root surface caries, like other types of dental caries, results from the interaction of a triad of factors, namely bacterial plaque, dietary carbohydrates and susceptible tooth surface.

Numerous microbiologic studies have identified the culprit bacteria as *Streptococci Mutans* and *Lactobacillus*.

Salivary gland dysfunction, leading to reduced salivary output, contributes to increased susceptibility to root caries by removing the buffering effects of the saliva and by decreasing the amount of mineral available for remineralization.

Dry mouth is most often produced by many commonly prescribed medications, chemotherapy and radiation treatment.

Preventing Root Caries

Simple prevention techniques like the use of fluoride appear to be quite effective in preventing root caries as well as arresting their development.

Chlorhexidine and especially fluoride varnishes are important tools for the prevention and chemotherapeutic treatment of root caries.

Preventive care can include: a fluoride dentifrice; annual bitewing radiographs (vertical bitewings if significant alveolar bone loss is present); quarterly to semiannual recall; fluoride var-

nish; application of topical, high concentration fluoride; daily fluoride rinse, fluoride gel 1.1% (neutral NaF) in trays; home care instruction; dietary counseling; bioactive glass or calcium phosphate containing pastes and antimicrobial therapy with or without monitoring *M. streptococcus* levels.

Diagnosing Carious Lesions

Because root caries are so aggressive and develop so quickly, general dentists, hygienists and periodontists need to work together closely.

Examination strategies should focus on those patients with known risk factors paying special attention to proximal surfaces.

Vertical bitewing radiographs are an excellent clinical examination because they permit better evaluation of the entire interproximal root surfaces.

Intraoral radiographs may not always be reliable because of “burn out” which may occur at the cemento-enamel junction seriously obscuring the radiographic evidence of early decay.

Treating Root Caries

Fluoride-releasing materials and metal ions contained in glass ionomer restorative materials may inhibit recurrent caries in restored root surfaces.

Resin-modified glass ionomers are useful since they bond to tooth structure, are esthetic and possess long-term fluoride release which can be replenished with topical fluoride applications.

Dentin bonding agents which incorporate antibacterial activity into their systems are also useful in inhibiting root caries.

Diagnosing, Treating and Avoiding Root Fractures

Teeth seem to fracture for two primary reasons: occlusal forces (chewing and parafunctional) which sometimes overload natural teeth, and fractures secondary to brittle roots due to endodontic treatment or large post spaces.

Trauma, such as chewing ice, biting into a cherry pit or bruxism may also contribute to fractures. These fractures often occur around existing restorations. Some of them can be treated with periodontal surgery to crown lengthen the involved tooth, thus exposing the fracture margin for restorative care.

Today, CT scanning makes it possible to diagnose some vertical root fractures not visible with conventional radiography.

These fractures can also be diagnosed by illuminating the inside of the tooth.

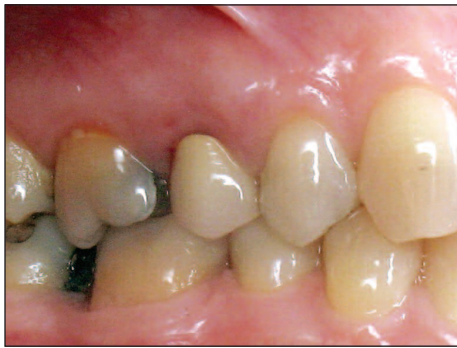

Figure 5. The upper right second bicuspid was previously restored with a post and crown and is tender upon chewing.

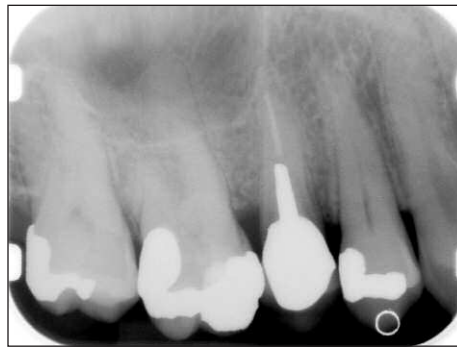

Figure 6. The initial radiograph does not reveal the cause of the patient's symptoms.

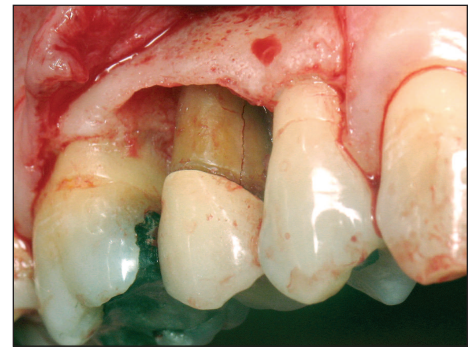


Figure 7. Flap reflection reveals a mesial vertical root fracture on tooth #4 which caused the tenderness on mastication. The tooth prognosis was hopeless.

Additional diagnostic information is gained from periodontal probing of the area. A vertical fracture will often share a very narrow and very deep pocket depth at the fracture site.

Root fractures are usually untreatable and these teeth are usually lost.

Root Fracture in Endodontically-Treated Teeth

Computer modeling studies indicate that periodontal bone loss increases the likelihood of root fracture in endodontically-treated teeth with posts. In these teeth, stress is concentrated at the apical end of the post and in the dentin lateral to this region.

The stress is higher and more concentrated in teeth with reduced periodontal support. It appears that fracture may be related to the decrease in dentin width near the end of the endodontic post.

For many years the rationale for the use of posts was not only to increase crown retention, but also to protect the tooth from fracture resulting from internal stress. Now studies show that endodontically-treated teeth without posts tend to fracture less than post-treated teeth and that it is the bulk of dentin in the region of the apex of the post that is most important in preventing fractures.

The amount of remaining supragingival tooth structure supporting the crown and post is also very important.

Some observers have also noted that endodontically-treated teeth without posts tend to fracture in a repairable manner while post crowns tend to experience total root fracture. Again, sufficient dentin at the apex of the post reduces the likelihood of these fractures. In fact, when there is adequate clinical crown length for cast crowns, retention posts are not necessary. In many cases, periodontal surgical crown lengthening can increase crown length, thus eliminating the need for posts.

Another potential problem with post placement is the perforation of the root surface wall during post space preparation. This occurs most frequently in situations of long post preparation in thin, tapering roots or on roots which have pronounced figure eight interproximal concavities not apparent on radiographs. The

root anatomy of mandibular molar roots, mesial roots of maxillary molars and the roots of maxillary first premolars often have pronounced concavities with the canal space close to the inner aspect of the roots. This makes these teeth questionable candidates for post placement due to the high risk of root fracture.

Root Sensitivity

Root sensitivity is usually the result of fluid shifts within the dentinal tubules induced by thermal changes or chemical gradients which stimulate free nerve endings in the pulpal tissues.

Causes of root sensitivity include injury to the dentin, gingival recession and acid produced by bacterial plaque.

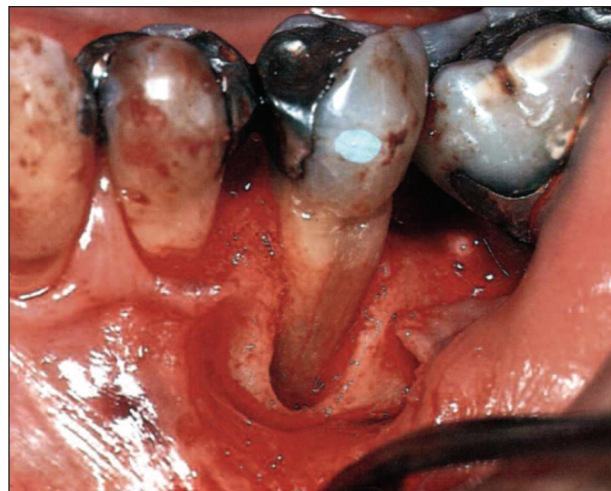

Figure 8. Vertical root fracture in an endodontically-treated tooth with complete loss of the buccal bone plate.

Defective and leaking restorations, excessive occlusal loading, some tartar control toothpastes as well as tooth whitening agents and dietary acids have also been implicated.

All of these conditions reduce or destroy a "smear layer" of debris which occludes portions of the dentinal tubules and demineralizes tooth structure.

Prevention of sensitivity by reducing its causes includes:

1. Improved supragingival plaque control
2. Occlusal correction of teeth in traumatic occlusion
3. Dietary and/or dentifrice changes to reduce smear layer loss
4. Replacing restorations with defective margins
5. Endodontic care for teeth with persistent pulpal irritation

Experience has shown that root sensitivity increases or decreases in direct proportion to the amount of acidic foods ingested.

Essential to diagnosing root sensitivity is both a careful history and thorough examination, including radiographs. Typically, the patient can readily identify the sensitive tooth or teeth and can describe the stimulus that initiates the pain. Exposed dentin is normally apparent as is loss of gingiva.

The examination must exclude the presence of dental caries and pulpal pathology, vertical cracks and cracked cusps, and leaking restorations. Touching the exposed dentin with an explorer, or a spray of cold air from the air-water syringe after isolating the suspected tooth will help confirm both the diagnosis and the area in need of treatment.

Managing and Treating Root Sensitivity

The objectives of treating root sensitivity are two fold: reduce the factors which heighten sensitivity and occlude dental tubules.

While desensitizing toothpaste most often manages mild tooth sensitivity, these agents require prolonged use before they are effective.

However, when patients report initially moderate or persistent root sensitivity, the causes should be examined further and possible secondary causes treated. If none of those factors is determined to play a major role, tubule-occluding treatment should be recommended.

Seven agents which occlude dentinal tubules have proven successful:

1. **Fluorides.** A 0.717 percent stannous fluoride solution can be applied in the office followed by the patient's daily use of 0.4 percent stannous fluoride gel. Sodium fluoride should be substituted at home if staining of stannous fluoride on restorative materials is a possibility. A fluoride varnish (Duraphat, Colgate Corporation) can be used as the in-office treatment. Duraphat is easy to apply with a small brush and saliva contamination is generally not a concern.
2. **Oxalates.** Potassium oxalate (Protect by Butler and Therma-Trol by American Dental Hygienics) and Ferric Oxalate (Sensodyne Sealant by Block Drug) deposit respectively potassium and iron precipitates which seal the dentinal tubules.
3. **Root coverage.** Isolated areas of root exposure with sensitivity may be candidates for root coverage with gingival graft surgery. This will also alleviate any cosmetic concerns caused by the recession.
4. **Dentin bonding agents.** Resin-based adhesive systems can provide a more durable and long lasting dentin desensitizing effect. They seal the dentinal tubules and modify the smear layer, incorporating it into a hybrid layer. Clinical trials have shown All Bond, Scotchbond, Gluma, Amalgambond, Pain Free, Root Surface Dentin Desensitization Kit by Bisco and Prime & Bond all produce good results.

5. **Bioglass.** A formulation of bioglass in a dentifrice can promote infiltration and remineralization of dentinal tubules. The bioactive glass converts to hydroxycarbonated apatite through the formation of a surface silica gel layer. This mineralizing surface bonds to and "seals off" the open tubule, thereby reducing the sensitivity. Two commercially available products are Renew and Oravive.

6. **Casein** (phosphopeptide-amorphous calcium phosphate). Recently, milk protein casein has been used to develop a remineralizing agent (GC Tooth Mousse) which may help in the prevention and treatment of dental hypersensitivity. Clinpro 5000 and MI paste which combine sodium fluoride with tricalcium phosphate are also available.

7. **Depolarizing Agents.** Depolarizing agents are basically potassium nitrate-containing products that desensitize by compromising the nerve's ability to transmit the painful response through depolarization of the nerve. These agents include products such as Ultradent and Relief ACP.

While the choice of approach is up to the individual clinician, treating root sensitivity beyond recommending a dentifrice offers a valuable service to those patients who experience moderate or severe sensitivity.

Since sensitivity is so subjective, the identification of causative factors and isolation and identification of sensitive areas is essential to developing a treatment regimen for managing sensitivity.

While not always successful, establishing a diagnostic regimen and a reasonably predictable treatment protocol will help to identify the causes of these difficult situations and ultimately benefit your patients by reducing unpleasant symptoms.

